



PATIENT

Pakalolo Gordon

SPECIES

Canine

BREED

Boston Terrier

SEX

Female Spayed

AGE

13 years

WEIGHT

17.1lbs

INTERPRETED BY

Maggie Machen Lamy,
DVM, DACVIM
(Cardiology)

IMAGING PERFORMED BY

Jessica Bailes

HOSPITAL NAME

All Creatures Great &
Small Veterinary
Clinic

REFERRING VET

Dr. Bailes

INVOICE

31365

DATE

6/15/23

PRESENTING CLINICAL SIGNS

History: Recheck echo. Progressive heart murmur. Reassess prior to surgery. BP today: 213mmHg (patient very quiet - received butorphanol today).

-Current medications: Pimobendan BID.

-Pertinent previous echo findings (9/2022 MML): Mild to moderate MR, mild LAE, no LVE, mild TR, mild PAH: 3.2m/s.

ECHOCARDIOGRAM FINDINGS

2D, m-mode, color flow and doppler imaging is available. Mild diffuse thickening of mitral valve leaflets with no prolapse into the left atrial lumen. Mild to moderate eccentric mitral regurgitation with mild to moderate left atrial dilation. Normal MR velocity. Normal LV diameter with adequate myocardial function. The tricuspid valve appears mildly thickened with mild tricuspid regurgitation. Velocity consistent with early pulmonary hypertension. Normal right atrial and ventricular diameter and morphology. The pulmonic and aortic valves are normal in morphology and mobility. Normal pulmonic and aortic outflow velocities with laminar flow. No obvious aortic or pulmonic insufficiency. No pericardial or pleural effusion noted. No obvious cardiac masses.

CARDIAC CHART

CANINE CARDIAC PARAMETERS	MR VMAX (m/s)	TR VMAX (m/s)	LA/AO (Boon method)	LA/AO (Heart Base; Swe)	FS (%)	EF (%)	EPSS (cm)
NORMAL PARAMETER	4.5-5.5	<2.7	1.3	<1.6	28-40	40-100	<0.6
PATIENT	6.5	3.3	1.3	1.6	62	91	0.1
CANINE CARDIAC PARAMETERS	HR (BPM)	AV VMAX (m/s)	PV MAX (m/s)	BODY WEIGHT (kg)	LA 2D short axis Base view (cm)	LVIDd Avg; 2D and m-mode short axis (cm)	LVIDs Avg; 2D and m-mode short axis (cm)
NORMAL PARAMETER	50-100	0.7-1.7	0.7-1.6	BELOW	BELOW	BELOW	BELOW
PATIENT	nm	1.5	0.7	7.8	2.0	2.9	1.1
*Normal chamber parameters expressed as a mean value (SD)				3	1.27 (5.3)	2.46 (2.46)	1.36 (5.5)
BODY WEIGHT DEPENDENT PARAMETERS				5	1.40 (4.5)	2.74 (5.2)	1.60 (4.7)
<i>*Note: All measurements based upon multi-modal images and methods. An average value is reported.</i>				10	1.50 (3.8)	3.27 (3.5)	2.06 (3.1)
				15	1.83 (2.0)	3.71 (2.4)	2.43 (2.1)
				20	2.02 (1.9)	4.14 (2.2)	2.80 (2.0)
				25	2.18 (2.4)	4.48 (2.9)	3.10 (2.5)
				30	2.33 (3.3)	4.83 (3.9)	3.39 (3.4)
				35	2.48 (4.3)	5.17 (5.0)	3.69 (4.5)
				40	2.62 (5.2)	5.48 (6.1)	3.96 (5.4)
				50	2.88 (7.1)	6.07 (8.3)	4.46 (7.4)

INTERPRETATION OF THE FINDINGS & FURTHER RECOMMENDATIONS

Compared to the prior study, findings are similar. The left heart dimensions are unchanged with mild to moderate MR. The TR remains mild with evidence of mild stable pulmonary hypertension. No additional issues are noted in this study.

Given these findings, continue Pimobendan as prescribed. Continued assessment of progression in the future will help predict long term prognosis, which is highly variable at this stage (B1/B2).



PATIENT

Pakalolo Gordon

SPECIES

Canine

BREED

Boston Terrier

SEX

Female Spayed

AGE

13 years

WEIGHT

17.1lbs

INTERPRETED BY

Maggie Machen Lamy,
DVM, DACVIM
(Cardiology)

IMAGING PERFORMED BY

Jessica Bailes

HOSPITAL NAME

All Creatures Great &
Small Veterinary
Clinic

REFERRING VET

Dr. Bailes

INVOICE

31365

DATE

6/15/23

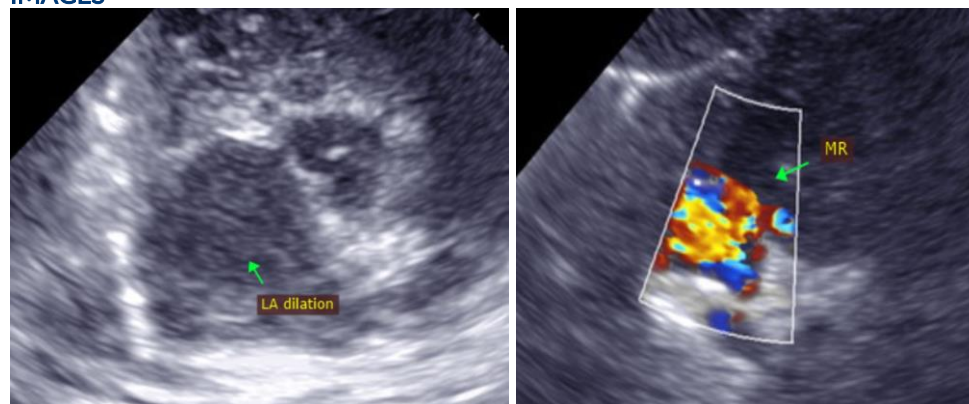
The reported blood pressure is elevated, and should be reassessed for accuracy particularly given no reported clinical signs of severe hypertension (retinal changes, etc) or evidence of LVH on echo. Ideally obtain serial measurements in a controlled, low stress environment and continue until 3 consecutive readings plateau within 5mmHg of variability. If persistently >180mmHg despite a relatively calm demeanor, recommend institution of amlodipine to effect. Additionally if deemed accurate, screening for predisposing underlying causes of SHT is recommended (Cushings, PLN, adrenal tumor, etc), as primary disease is relatively uncommon and a rule out diagnosis.

Omega fatty acid supplementation and mild salt restriction may be of some long-term benefit. Monitor for development of a cough, labored breathing, exercise intolerance or collapse episodes.

Anesthetic risk is considered mild if needed. Cardiac protective drug choices (opioid/benzodiazepine premedication, propofol or alfaxalone induction, isoflurane gas) are recommended. Pre-oxygenate for 5-10 minutes prior to induction. Monitor for arrhythmias, hypotension, and hypoxia both intra and post-operatively and intervene as necessary. Mild IV fluid restriction is recommended to avoid fluid overload. Avoid heart rate stimulating drugs such as atropine unless clinically indicated.

Recommend conservative monitoring with a recheck echocardiogram in 6 months, sooner if any development of clinical signs.

IMAGES



The information and recommendations provided are based on the images presented by the referring veterinarian. No evaluation can be communicated regarding pathology that was not visible in the image/video clips provided.

Thank you for this referral. This report was generated using transcription software, and minor dictation errors may be present. If the clinical or image interpretation does not parallel your findings or if I can be of any further assistance, please contact me.

Maggie Machen Lamy, DVM
Diplomate of the American College of Veterinary Internal Medicine (Cardiology)
info@sonopath.com



PATIENT

Pakalolo Gordon

SPECIES

Canine

BREED

Boston Terrier

SEX

Female Spayed

AGE

13 years

WEIGHT

17.1lbs

INTERPRETED BY

Maggie Machen Lamy,
DVM, DACVIM
(Cardiology)

**IMAGING
PERFORMED BY**

Jessica Bailes

HOSPITAL NAME

All Creatures Great &
Small Veterinary
Clinic

REFERRING VET

Dr. Bailes

INVOICE

31365

DATE

6/15/23